



Manifestation of Onchocercal Skin Disease among selected Communities in Central Taraba State, Nigeria

¹Danladi, T., ²Elkanah, S.O., ²Elkanah, D.S., ³Madara, A.A., ⁴Kela, S.L and ²Williams, G.

¹Department of Zoology, Adamawa State University (ADSU), P.M.B. 25, Mubi, Adamawa State, Nigeria.

²Applied Zoology unit, Department of Biological Sciences, Taraba State University, PMB 1167, Jalingo, Taraba state.

³Department of Biological Sciences University of Abuja, , PMB 117, Abuja FCT. ³

⁴Department of biological Sciences, Federal University of Kashere, Gombe State.

Contact: thomasdanladi9@gmail.com : +2348037725303

Abstract

Onchocerciasis is a major health and socio-economic problem caused by *Onchocerca volvulus*. The prevalence and intensity of human Onchocerciasis has been reported at the Taraba river valley by Akogun and Onwuliri over twenty years ago. In a cross sectional epidermiological study by Rapid Assessment Method, 326 individuals were examined of onchocercal skin diseases in 8 communities across central Taraba State. Of the 326 adults examined, 54 (16.60%) had nodules, 28 (8.61%) manifested Onchodermatitis, 50 (15.33%) had leopard skin while 1.53% and 14.11% of the population showed hanging groin and elephant skin respectively. There was no significant difference in sex related infection ($\chi^2=0.1980$, $P>0.05$). Qualitative research methodologies (questionnaire and in-depth interview) were employed to investigate social and psychological aspect of Onchocercal skin disease. The result showed little or no knowledge of the aetiology of the disease and this influence the health seeking behaviour of members of the communities visited. People with Onchocercal skin disease exhibit withdrawal tendencies and low self-esteem because of erroneous traditional beliefs. The social and psychological implications of Onchocercal skin disease emanating from the findings were discussed.

Keywords: Onchocerciasis; Leopard skin; Onchodermatitis; Hanging groin; Taraba State.

Introduction

Onchocerciasis is a chronic parasitic disease caused by the filarial nematode *Onchocerca volvulus* and is transmitted by different species of blackflies (WHO, 2009). Onchocerciasis is a wide spread filarial disease that produces grave socio-economic effects. The impact of the disease in social, economic and cultural terms has been shown to be enormous as it affects the productivity, social and sexual lives of sufferers due to blindness and other debilitating effects (Nwoke, 2008).

The disease is found in 28 countries in Africa, Latin America, Yamen, and Nigeria alone accounts for the highest number of infected persons in African continent (WHO, 1995). Thirty one of the existing 36 States of Nigeria and the Federal Capital Territory have meso to hyper endemic foci for Onchocerciasis (NOCP, 1996). Out of the 774 Local Government Areas (LGAs) in Nigeria, about 416 are rated high priority for Onchocerciasis control (NOCP, 1996). In this study, manifestation

of Onchocercal skin disease in some selected communities of Ardo-Kola and Yorro Local Government Areas of Taraba State was determined and the need to halt these manifestations.

Materials and Methods

Taraba State lies approximately between Latitude 6°25' and 9°30'N and Longitude 9°30' and 11°45'E. It is bordered on the West by Nassarawa and Plateau State, South East by Bauchi and Gombe States, North East by Adamawa State and South west by Benue State. Taraba State is bordered to the East by the Federal Republic of Cameroon which is an international boundary. Majority of the people in the state are living in rural settlement consisting of hamlets and villages. Majority of the inhabitants live in rural agricultural areas with farming as the major occupation. The two L.G.As has numerous streams traversing villages/communities and draining into the major river Benue. Communities rely mainly on the streams and river for water supply.

Ethical considerations

A pre-survey visit to the Local Government Headquarters at Gashaka was carried out. The intent and justification for the study was discussed with the Local Government officials including the Director, Primary Health Care Unit. Additional permission was sought and obtained from District Heads, Village Heads and communities leaders within the study localities before commencement of the study

Rapid Assessment Method

On the schedule day, informed oral consent of individuals who gathered at the agreed venue (Village head compound, school and church premises) were sought and obtained after the explanation of the procedures and the benefit of the study before they were examined in secrecy for clinical signs and symptoms of Onchocerciasis by the criteria of Edungbola *et al.* (1993). Clinical symptoms such as Lymphoedema of limbs, breast and Scrotal Elephantiasis were recorded in personal data form containing the patient’s name. Female examination was restricted to the legs, arms and breast because of cultural inhibitions in most communities.

Data Analysis

Data obtained was analysed using chi-square test to evaluate the occurrence of Onchocercal skin disease between different communities.

Results

The prevalence rates of the various manifestations of Onchocerciasis considered in the study area is shown in Table 1. Kumfan recorded the highest number of onchocercal skin disease with 92.59% followed by Nyibango (70.37%) and the least was Sarti (32.26%). Of the 326 adults examined 16.60% had Nodules, 8.61% manifested Onchodermatitis, 15.33% had Leopard skin, while 1.5% and 14.11% showed Hanging groin and Elephant skin respectively (Table 2). Chi square analysis did not show significant difference in occurrence between gender ($\chi^2=0.1980$, $p>0.05$). However, there was variation in the occurrence of the disease among the different communities ($p<0.05$).

Plate 1,2,3,4,5,6,7 and 8 shown the various onchocercal skin diseases recorded from the study areas. Plate 1 shows the leopard skin, plate 2 shows Nodule beside the armpit, plate 3 shows Dermatitis on the face plus blindness, plate 4 shows the lizard skin and Depigmentation, plate 5 shows Elephant skin, plate 6 shows Depigmentation of the hand, plate 7 shows popular dermatitis on the legs and plate 8 shows the Hanging Groin respectively.

Table 1: Prevalence of Onchocercal skin disease according to communities

Communities	No. examined	No. with signs	Percentage (%)
Bodel	43	28	65.12
Jamtari	50	35	70.00
Nyabar	38	22	59.89
Kumfan	27	25	92.59
Gamen	33	25	52.3
Gayam	60	37	60.12
Nyibango	44	30	70.37
Serti	31	10	32.26
Total	326	212	65.0

Table 2: Distribution of Onchocercal skin disease and nodules

Communities	No. examined	Nodules		Dermatitis /Itching		Leopard skin		Hanging groin		Elephant skin	
		No.	%	No.	%	No.	%	No.	%	No.	%
Bodel	43	6	13.90	2	4.65	9	20.95	0	0.00	7	12.01
Jamtari	50	7	14.00	5	10.00	9	18.00	0	0.00	8	16.01
Nyabar	38	7	18.42	3	7.89	3	7.89	0	0.00	4	10.01
Kumfan	27	8	29.63	5	18.52	2	11.11	0	0.00	5	17.10
Gamen	33	5	16.67	3	4.17	6	20.83	2	8.33	5	18.01

Gayam	60	12	18.18	5	8.33	9	13.64	2	3.33	6	10.13
Nyibango	44	7	14.81	3	7.40	9	22.22	1	2.50	9	25.22
Serti	31	2	6.45	2	6.45	3	9.68	0	0.00	1	3.23
Total	326	54	16.60	28	8.61	50	15.33	5	1.53	45	14.78

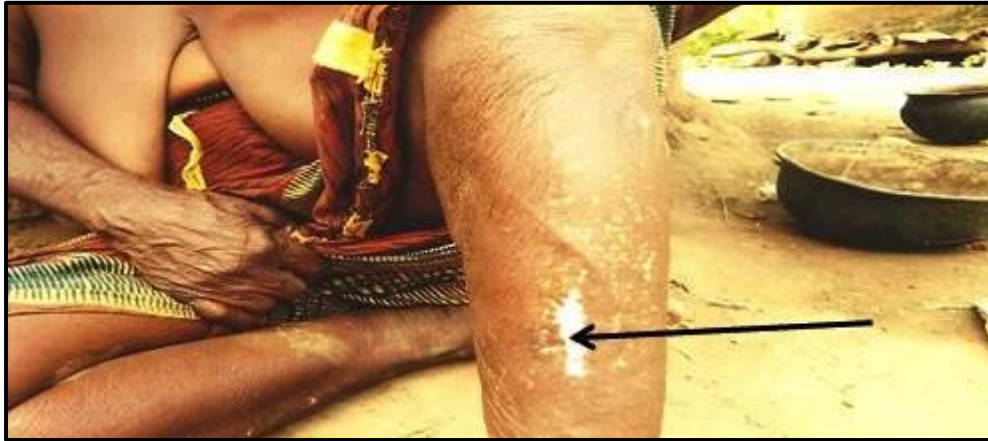

Plate 1: Leopard skin (arrowed)

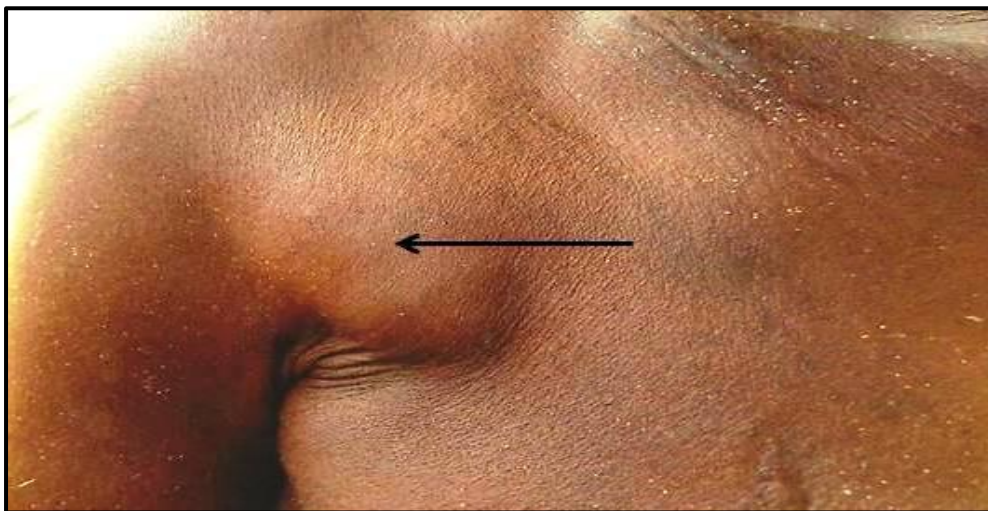


Plate 2: Nodule beside the Armpit (Arrowed)



Plate 3: Dermatitis on the face + Blindness (Arrowed)

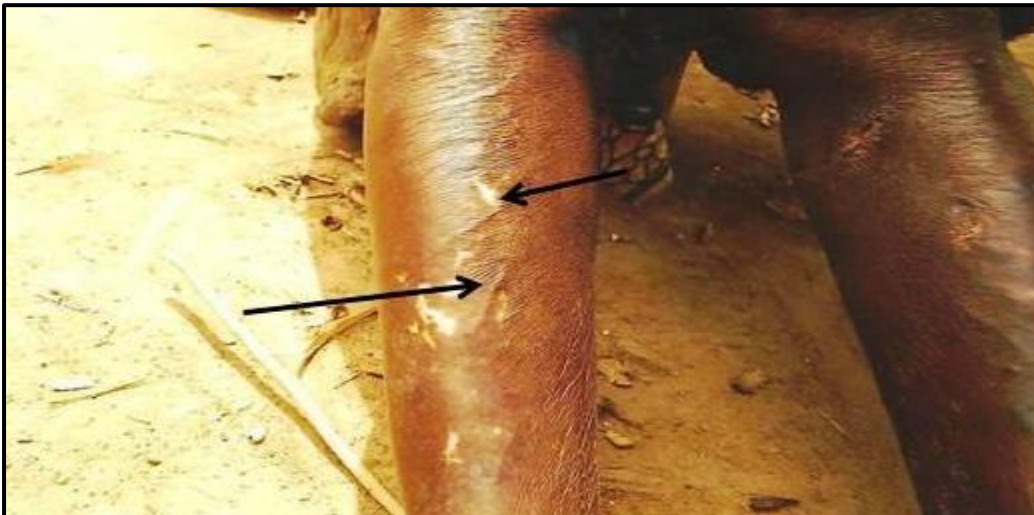


Plate 4: Lizard Skin and Depigmentation (Arrowed)



Plate 5: Elephant Skin

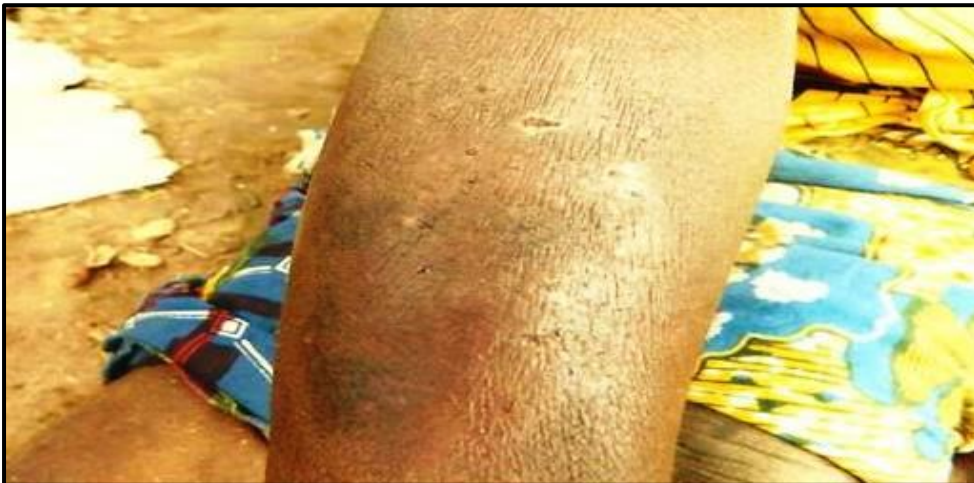

Plate 6: Depigmentation of the Hand

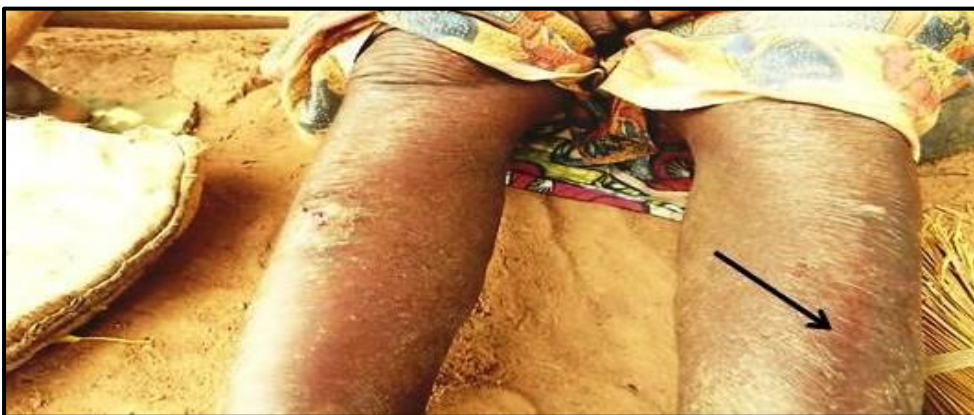

Plate 7: Papular dermatitis on the Legs (Arrowed)

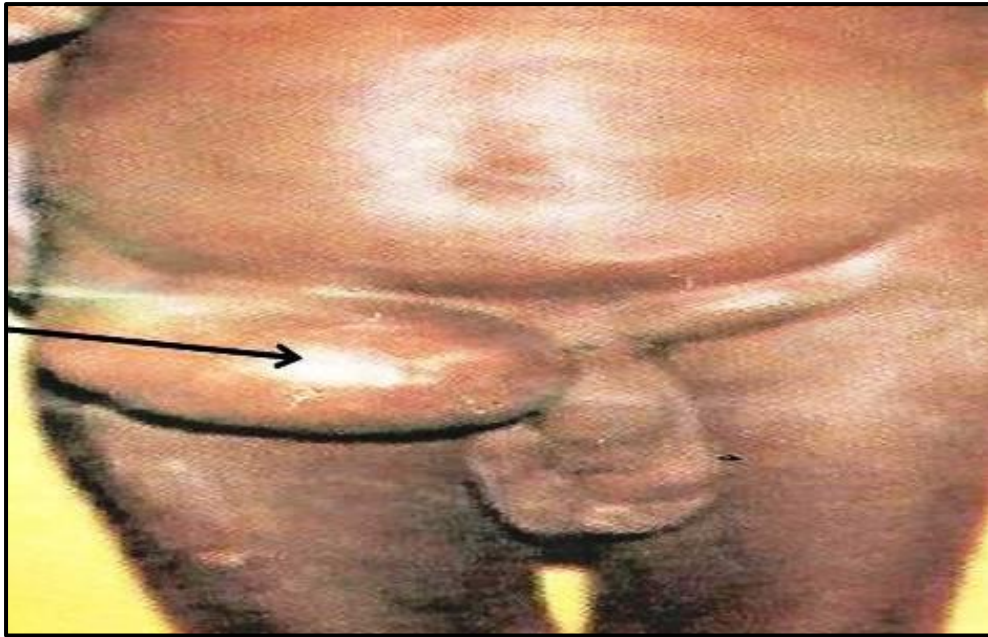

Plate 8: Hanging Groin (Arrowed)




Plate 9: Onchocercal Nodule on the head (Arrowed)

Discussion

The overall onchocercal skin disease of 65% recorded in this study indicates the endemicity of the disease in these eight communities. The endemicity of the disease may have been enhanced by the presence of the perennial Taraba River and its associated rivlets which while providing water for the domestic need of the community, also serve as breeding sites for the black fly – *Simulium* species (Akogun and Onwuliri, 1991; Elkanah *et al.*, 2010).

The most common consequence of Onchocerciasis is blindness, but the severe skin diseases and

associated intense itching cause chronic suffering and severe disability to affected individuals. Our findings on the consequences of Onchocercal Skin Disease in the area suggest that the sufferers were socially less well adjusted, less confident, anxious, shy, self conscious of their skin condition and experience delay with marriage proposals as observed by Amazigo (1994).

The result of this study showed that the decline in the indices of the disease is not significant even after twenty years of Mass Drug Administration in some parts of the River valley. Our finding is in contrast with that of Uzoigwe *et al.* (2012) who

reported a significant reduction in the disease indices after nine years of chemotherapy with ivermectin in some parts of Nasarawa State. Therefore, there is need for more effective method of the drug distribution and intensive enlightenment campaign to encourage people to comply with CDTI directives for onchocercal control.

Acknowledgment

The authors appreciate the effort of Mallam Habu Gashaka for logistic support and thank the chairman and Director of Primary Health Care of the L.G.A for his collaboration to carry out this research.

References

- Amazigo,U.O.(1994). Detrimental effects of Onchocerciasis on marriage age and breast feeding . *Tropical and Geographical Medicine*,46: 322-325
- Akogun, O. B. and Onwuliri, C. O. E. (1991). Hyperendemic Onchocerciasis in the Taraba River valley of Gongola State (old Adamawa Province), Nigeria. *Annals of Parasitology and Human Development*,**66(1)**: 22-26.
- Edungbola, L. D., Nwoke, B. E. B., Onwuliri, C. V., Akpa, A. U. C. and Tayo-Mafe, M. (1993). Selection of Rapid Assessment methods for community diagnosis of onchocerciasis in Nigeria. A recapitulation. *Nigerian Journal of Parasitology*.**14**: 3-10
- Elkanah, S.O., Debby-Sambo, E.O and Williams,G. (2010). Re-assessment of clinical Onchocerciasis in Gashaka Local Government Area, Taraba state. 34th Annual conference of Parasitology and Public Health Society, held on 21-25 September 2010 at FUT Oweri.Book of Abstract No 94.
- NOCP (1996).Federal Ministry of Health and Social Services.National Onchocerciasis Control programme.Revised National Plan of Action for the Control of Onchocerciasis in Nigeria(1997-2001).
- Nwoke, B.E.B. (2008). Parasitology in public health and neglected tropical diseases: The Nigerian situation. A lead paper at the 32nd Annual conference of Parasitology and Public Health Society of Nigeria (PPSN) Calabar, Nigeria, 24th – 27th September 2008
- Uzoigwe, N.R., Ajayi, J.A.A., Anyanwu, G.I., and Onyeka, J.O.A. (2012). Changes in prevalence of parasite intensity following ivermectin therapy against River blindness in

Woven community of Nasarawa state, Central Nigeria. *Nigerian Journal of Parasitology*, 33(2): 157 – 16

World Health Organization (2009). *African Programme for Onchocerciasis Control (APOC)*.

Retrieved January 22, 2009 from <http://www.who.int/blindness/partnerships/APOC>

WHO (1995). Onchocerciasis and its Control , WHO Technical Report Series No.852.